

2022-11-05 14:45:58

Data for reference only:

<< Conclusions >>

Name :pa im  
Sex :Female Age :80  
Section: Iq  
RoomID:  
BedID:  
ID:  
Operator: hh  
Custom1:  
Custom2:  
Custom3:

HR [bpm] : 67  
PR Interval [ms] : 199  
P Duration [ms] : 104  
QRS Duration [ms] : 71  
T Duration [ms] : 232  
QT/QTc [ms] : 394/415  
P/QRS/T Axis [deg] : 67.7/60.2/59.8  
R(V5)/S(V1) [mV] : 1.14/0.27  
R(V5)+S(V1) [mV] : 1.41

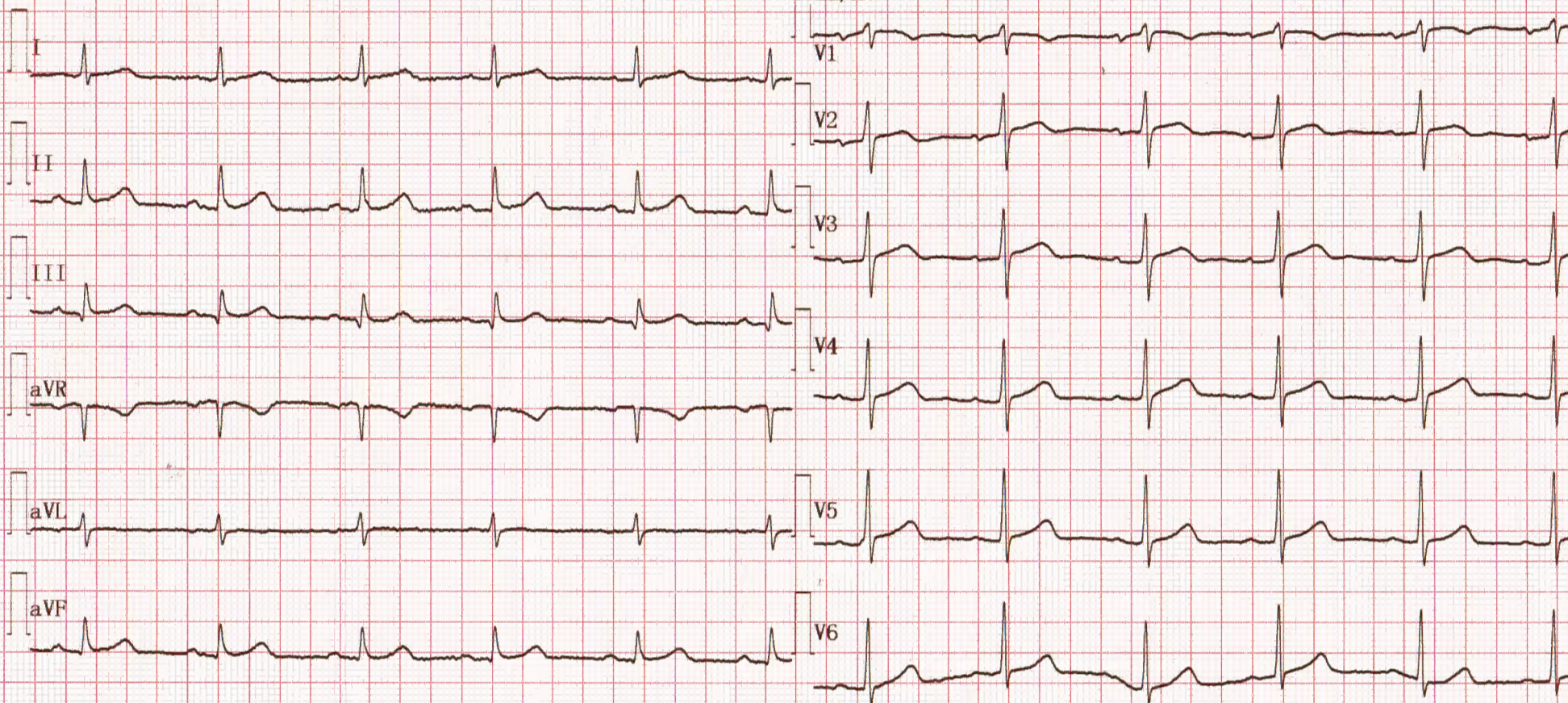
Normal Sinus Rhythm;  
Cardiac electric axis normal;

**\*\*Report need physician confirm\*\***

Physician: \_\_\_\_\_

AUTO 10mm/mV

10mm/mV



II 10mm/mV  
25mm/s EMG25Hz



**ឯកទេសទឹកនោមផ្អែម និងបេះដូង**  
**DIABETES & CARDIOLOGY SPECIALIST**

វេជ្ជ. ឌុច សុខេន ឯកទេសទឹកនោមផ្អែម និងទូទៅ  
វេជ្ជ. ឡេង ឆាយ ឯកទេសសន្លាក់  
វេជ្ជ. អៀន ប៊ុលរាតានកៈ ឯកទេសបេះដូង និងសរសៃឈាម

**Full Name** : TAE EM                      **Gender** : Female                      **PatientId** : 52-359-1  
**Document#** : 0000332                      **Report Date** : 22-Apr-2026                      **Request Date** : 22-Apr-2026  
**Request By** : Dr.Bolrathanak

**REPORT: HEART ULTRASOUND-WHOLE**

**FINDINGS:**

Aortic root : normal, D= 26mm, no aneurysm neither dissection  
Left atrium : not enlarged, LA surface area= 14cm<sup>2</sup>, no thrombus neither spontaneous contrast.  
Cardiac shunts : no shunts visible  
Left ventricle :  
o LV dimension: not enlarged with LVDd= 35mm. Good LV systolic function with LVEF= 67% <sup>TM</sup>  
o No wall motion abnormality.  
o Interventricular septum and posterior wall: no hypertrophy  
Mitral valve : trivial MR, no MS, mitral inflow: E/A=1.1 , Lateral E/e'=10.7  
Aortic valve : normal, no AR, no AS  
Right ventricle : no evidence of right cavity dilated. Good RV function, TAPSE=24 mm  
Tricuspid valve : no TR, No TS, neither pulmonary artery hypertension  
Pulmonary valve: no PR, no PS  
Pericardium : no effusion  
IVC : not dilated with 10 mm diameter, and > 50% respiratory collapsibility.

**CONCLUSIONS:**

Cardiac ultrasound is within normal limit for the age.

**Doctor's Name and Signature**

**Dr.Bolrathanak**

