

2022-11-29 09:49:17

Data for reference only:

<< Conclusions >>

Name : sim bora

Sex : Male Age : 45

Section: 50

RoomID: _____

BedID: _____

ID: _____

Operator: hh

Custom1: _____

Custom2: _____

Custom3: _____

HR	[bpm]	: 80
PR Interval	[ms]	: 196
P Duration	[ms]	: 120
QRS Duration	[ms]	: 75
T Duration	[ms]	: 200
QT/QTc	[ms]	: 351/406
P/QRS/T Axis	[deg]	: 66.7/45.6/24.1
R(V5)/S(V1)	[mV]	: 1.81/0.45
R(V5)+S(V1)	[mV]	: 2.26

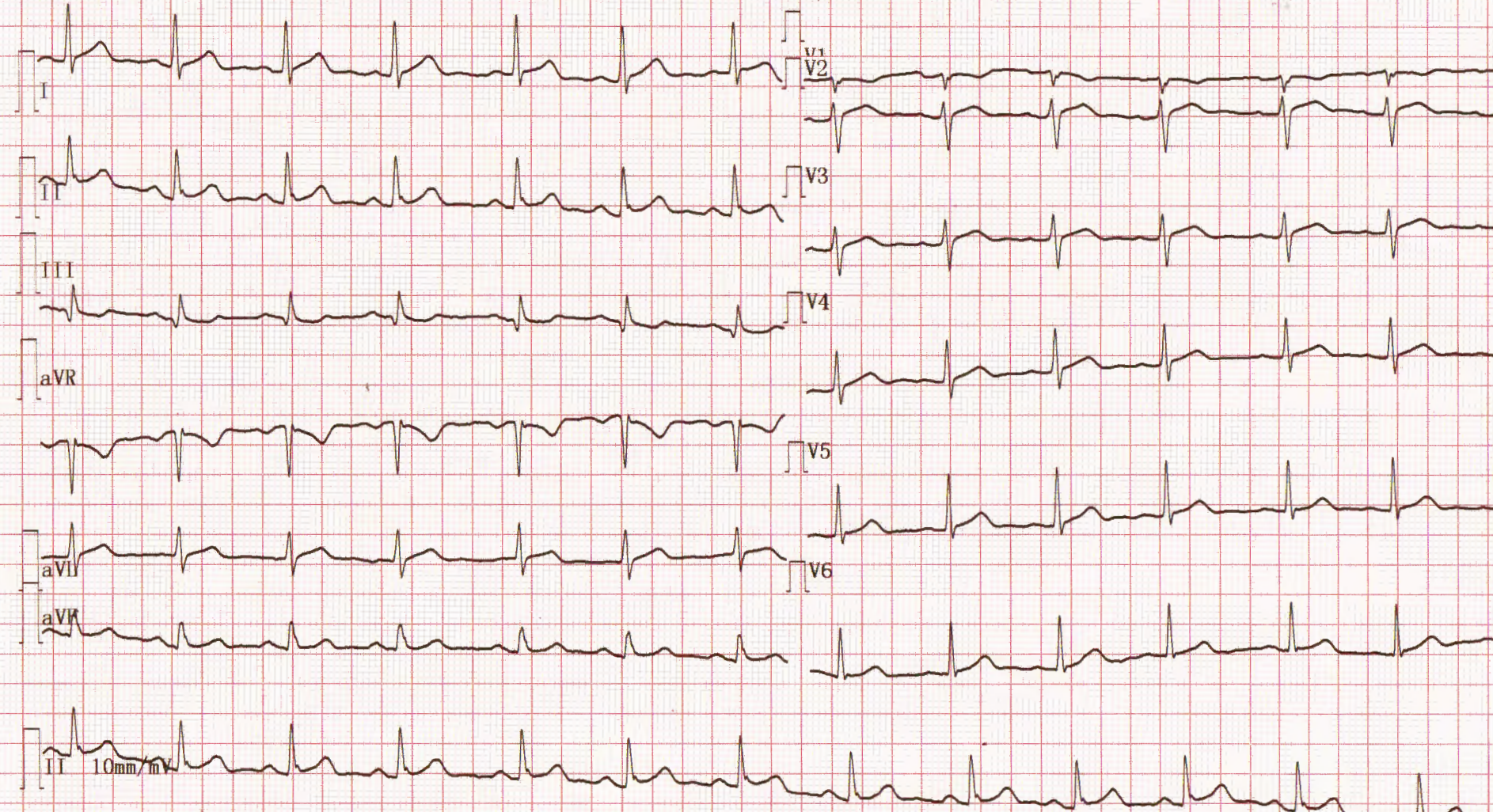
Normal Sinus Rhythm;
Cardiac electric axis normal;

****Report need physician confirm****

Physician: _____

AUTO 10mm/mV

5mm/mV



25mm/s EMG25Hz